Imaging in post operative cranium

Dr Pavankumar, Resident, Department of Radiodiagnosis - Aster CMI, Bengaluru, Karnataka
Head of the Department – Dr Sudhirkumar Kale

35th annual IRIA conference of Karnataka state chapter, 16th and 17th March - 2019

Surgical procedure

Burr hole

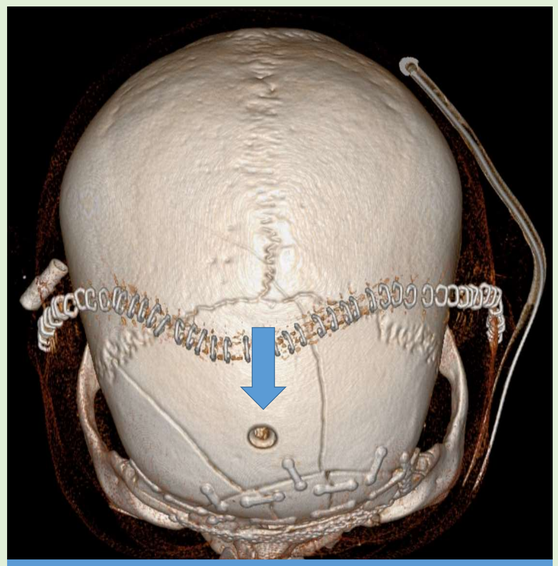

Burr hole is a small hole that is created in the calvaria with a surgical drill, usually to insert a device (eg, a ventricular drain or shunt catheter, endoscope, intracranial pressure monitoring device, or deep brain stimulator electrode), to provide access for stereotactic brain biopsy, to drain a chronic subdural hematoma.

Craniotomy

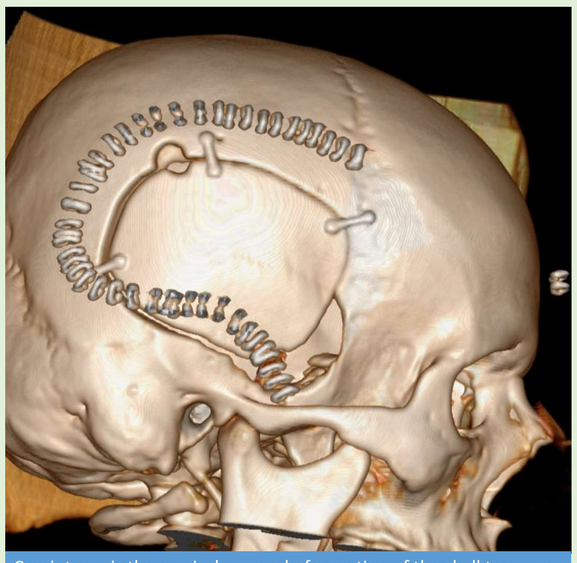

Craniotomy is the surgical removal of a portion of the skull to expose the intracranial contents. The bone flap is replaced at the end of the procedure and thereafter is identified according to its location (eg, frontal, bifrontal, parietal, occipital)

Craniectomy

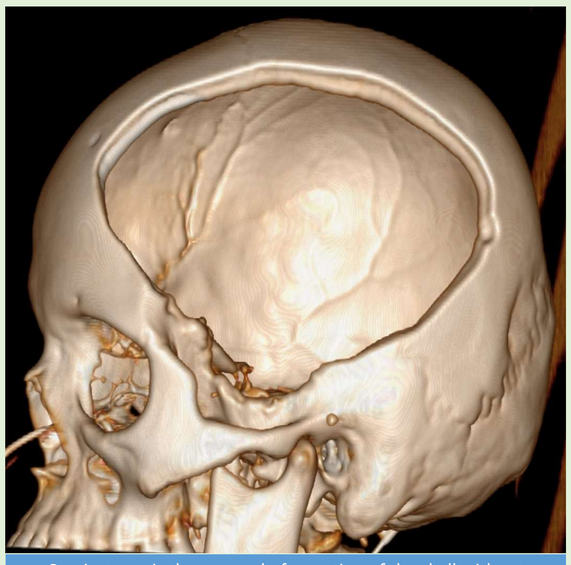

Craniectomy is the removal of a portion of the skull without subsequent replacement of the bone. It may be performed to remove an infected bone flap from previous craniotomy or a tumor that has infiltrated the calvaria. It also may be performed as part of a suboccipital approach to avoid postoperative compression of posterior fossa contents or as a primary procedure to decompress intracranial contents

Cranioplasty

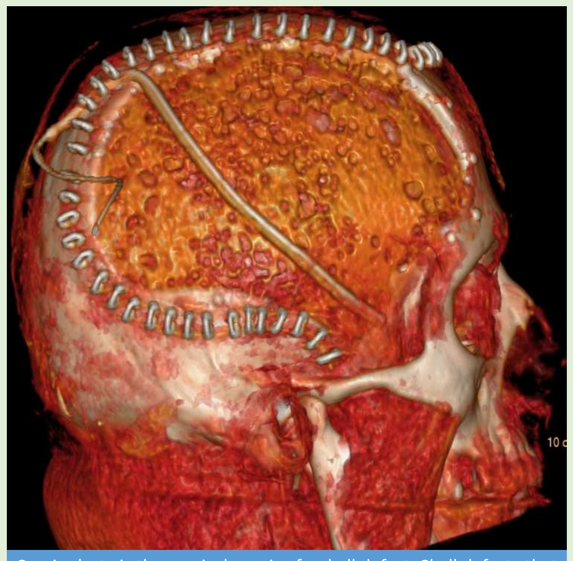

Cranioplasty is the surgical repair of a skull defect. Skull defects that require cranioplasty are most often the result of craniectomy, but they also may be congenital, a result of trauma (eg, a leptomeningeal cyst), or tumor related. Skull defects are repaired to restore cerebral protection, improve cosmesis, relieve discomfort, normalize intracranial pressure relationships, and provide an intact skull vault for normal calvarial growth and development

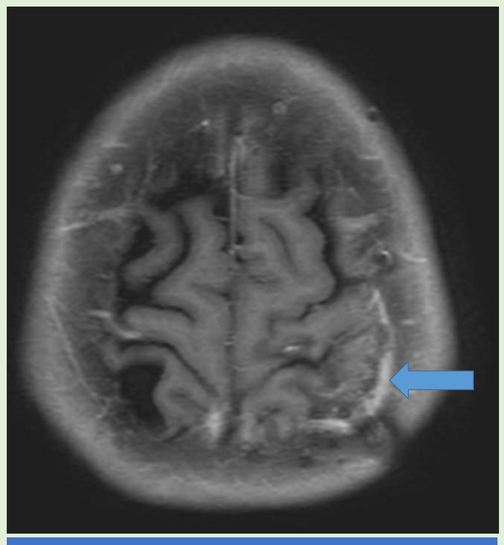

The dura mater enhances in a smooth linear pattern as soon as 9 hours after surgery, and enhancement can last as long as 40 years. It almost always occurs in the portion of the dura mater that is deep to the flap

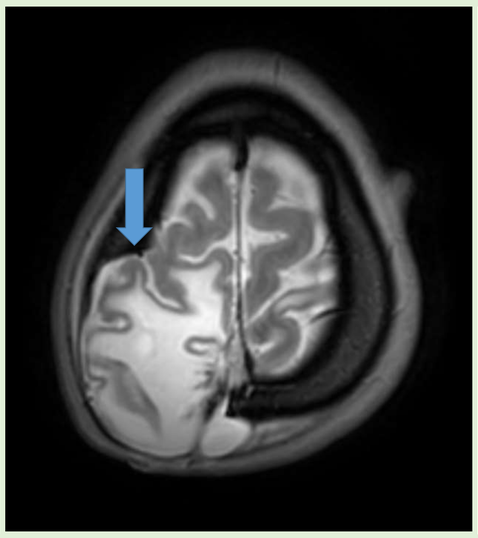

Extracranial herniation - If the craniectomy defect is too small, the swollen brain may herniate through the defect. This can result in compression of cortical veins and lead to venous infarction and contusion of the brain at the craniectomy margins

Infection - Appearances in the brain are typical of cerebral abscess but note the broad base at the level of the craniotomy with bone erosion. On that basis the bone flap is infected and the underlying brain secondarily involved.

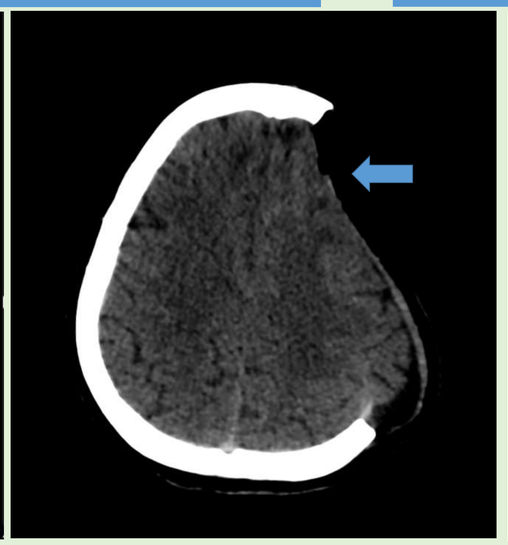

Trephine syndrome/sunken flap syndrome - The pathophysiology of this condition is thought to result from exposure of the intracranial contents to atmospheric pressure, which alters CSF hydrodynamics, deforms the brain, and reduces cerebral perfusion.

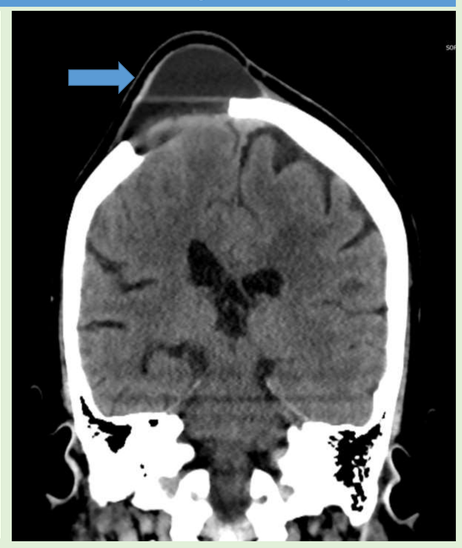

Psueodmeningocele - In some cases, the dura mater is left open and sutured to the bone margins around the craniectomy site to isolate the subdural space and limit the spread of postoperative fluid collections. If the dura mater remains open, the subarachnoid space may herniate outward through the defect and produce a pseudomeningocele

Post operative findings and complications

Pneumocephalus - Some amount of intracranial air is inevitable after craniotomy, Pneumocephalus most often occurs in the subdural space over the frontal lobe or lobes Tension pneumocephalus is a neurosurgical emergency; although similar findings may be seen at imaging in asymptomatic patients, the diagnosis should be made only if clinical deterioration accompanies imaging findings

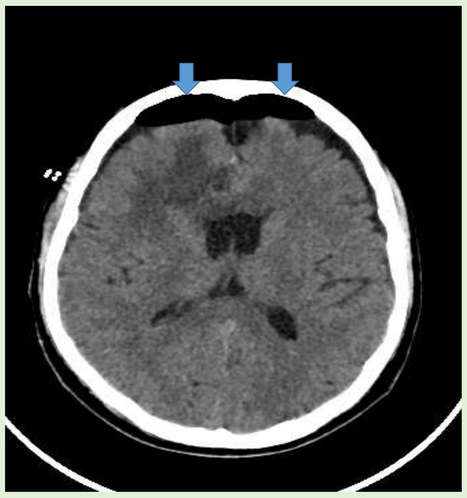

Extradural hematomas occur between the outer periosteal layer of the dura mater and the inner table of the skull. They are classified as regional, adjacent, or remote, Postulated causative factors include separation of the dura mater from the inner table of the skull at the craniotomy margins, possible cause is abrupt separation of dura mater from the inner table of skull

Acrylic cranioplasties are radiolucent, and at CT they have mixed intermediate and low attenuation. They often contain gas bubbles, which form during exothermic polymerization and should not be mistaken for a sign of infection.

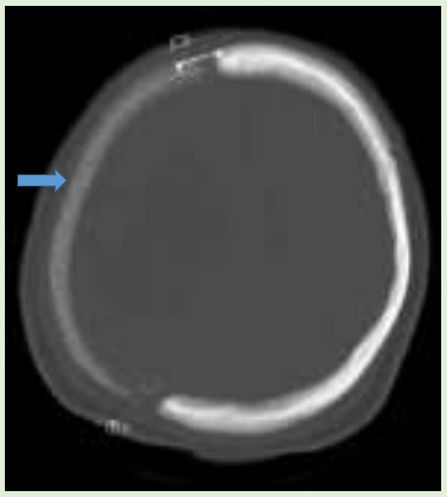

subgaleal hygroma - Disturbance of CSF circulation after craniectomy results in the formation of a subdural or subgaleal hygroma. Most of these collections are ipsilateral to the craniectomy site. Less often they are seen contralaterally, and they rarely are found in the interhemispheric space

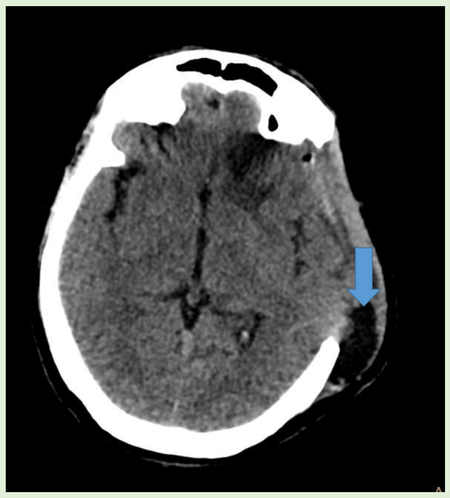

Paradoxical herniation- Patients with a large craniectomy defect who then undergo CSF drainage (eg, lumbar puncture, external ventricular drainage, ventriculoperitoneal shunting) have a resultant decrease in CSF pressure, which leads to a reduction in intracranial pressure and vulnerability of the cranial contents to atmospheric pressure. It is a neurosurgical emergency